

Extracellular Matrix For In-vivo Tissue Engineered Valve Repair And Reconstruction

Marc W. Gerdisch, MD; Akindolapo O. Akinwande, MD; Robert G. Matheny, MD;
St. Francis Heart Center, Indianapolis, Indiana, United States

Abstract

A fundamental limitation to remodeling or replacement of cardiac structures is the lack of synthetic or xenograft material that can be implanted without inducing inflammation and scar formation. Xenografts offer early performance advantages but the immunologic rejection of these materials leads to calcification and degeneration. The consequences of scar formation and calcification will depend on the site of implantation. Use of extra cellular matrix (ECM) and the resultant growth of site specific tissue offers the promise of repair or replacement of cardiac structures with no residual foreign body. This is essentially, auto grafting from a cellular level. With the cases here described, we took the first steps of intra-cardiac repair using ECM and have documented ongoing anatomic and performance integrity.

Objectives:

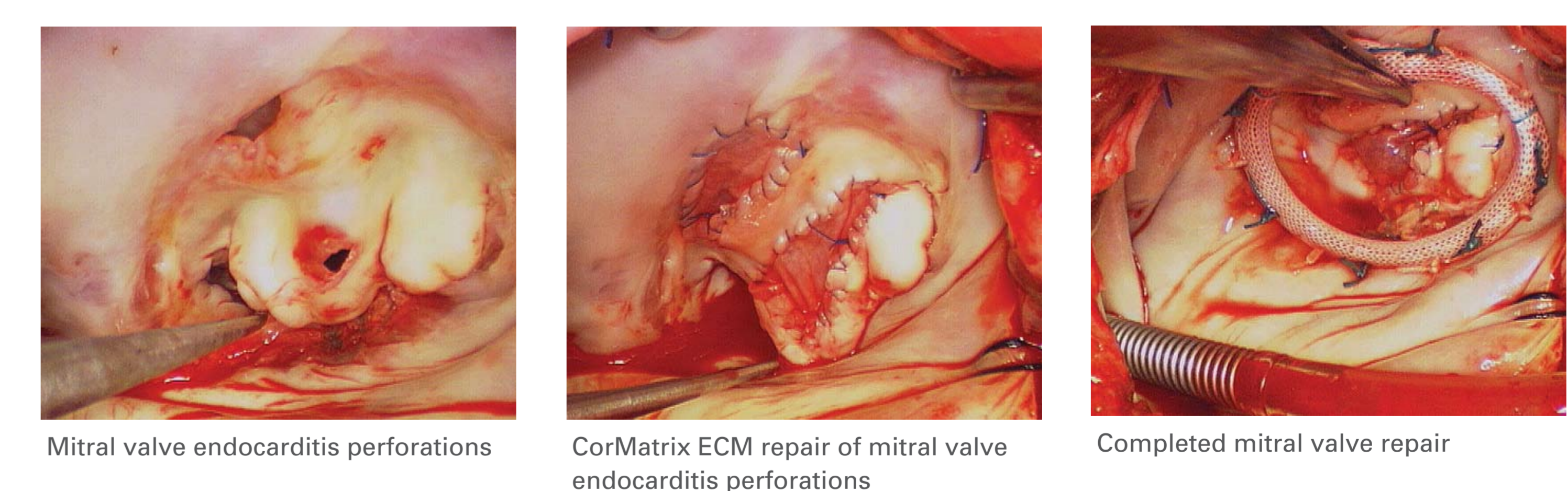
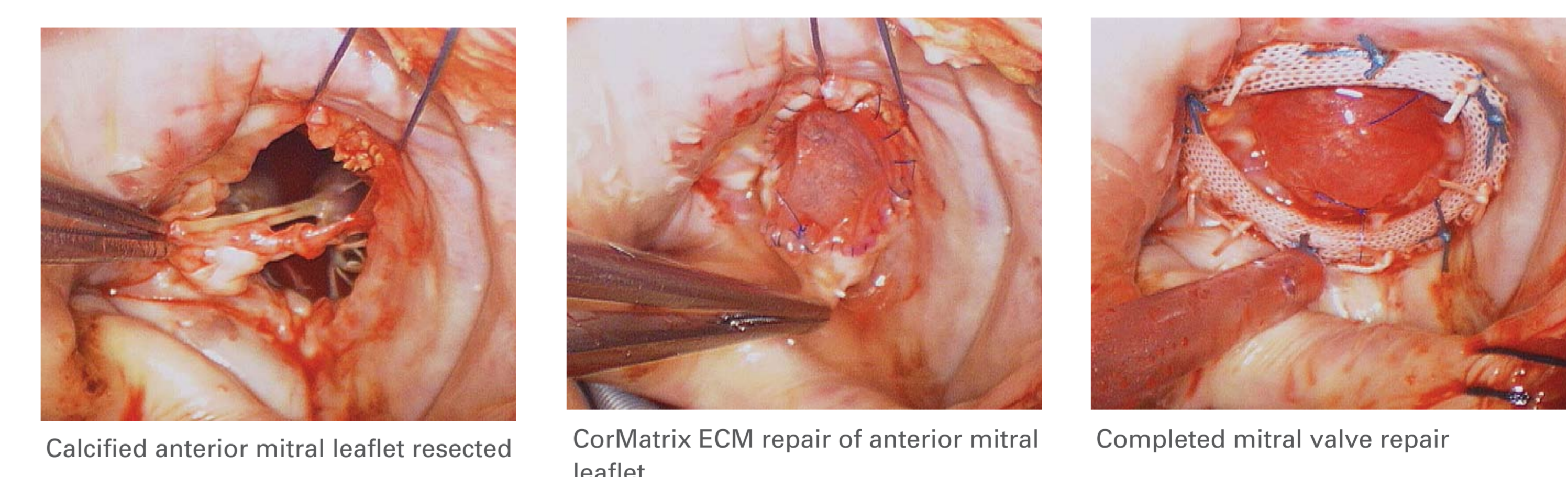
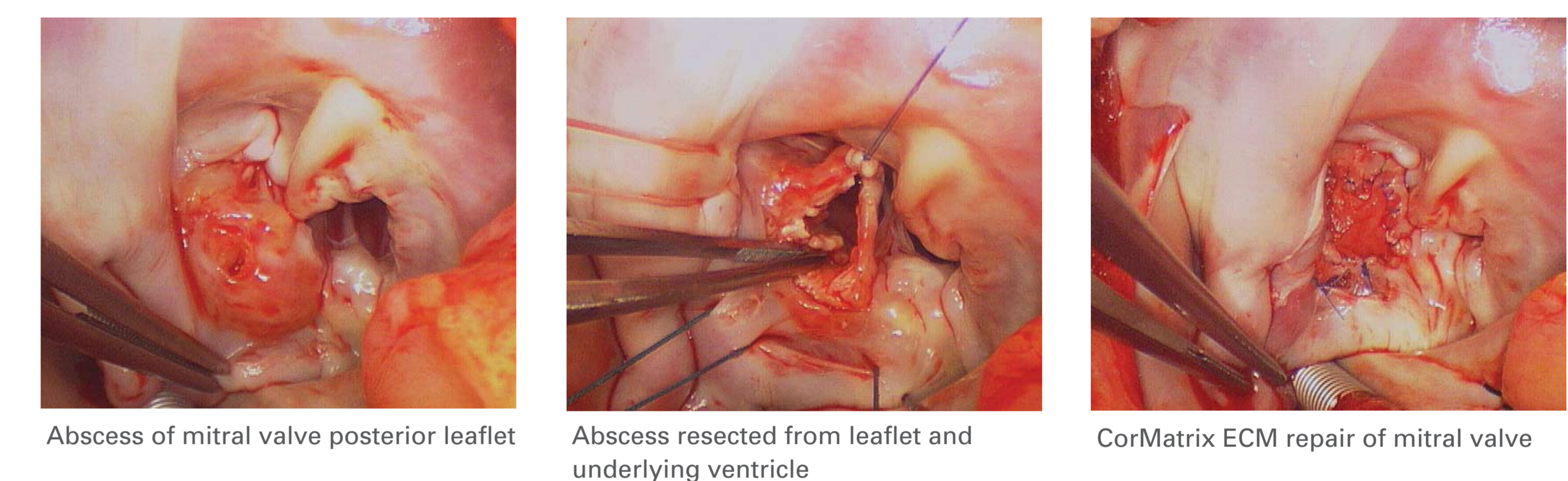
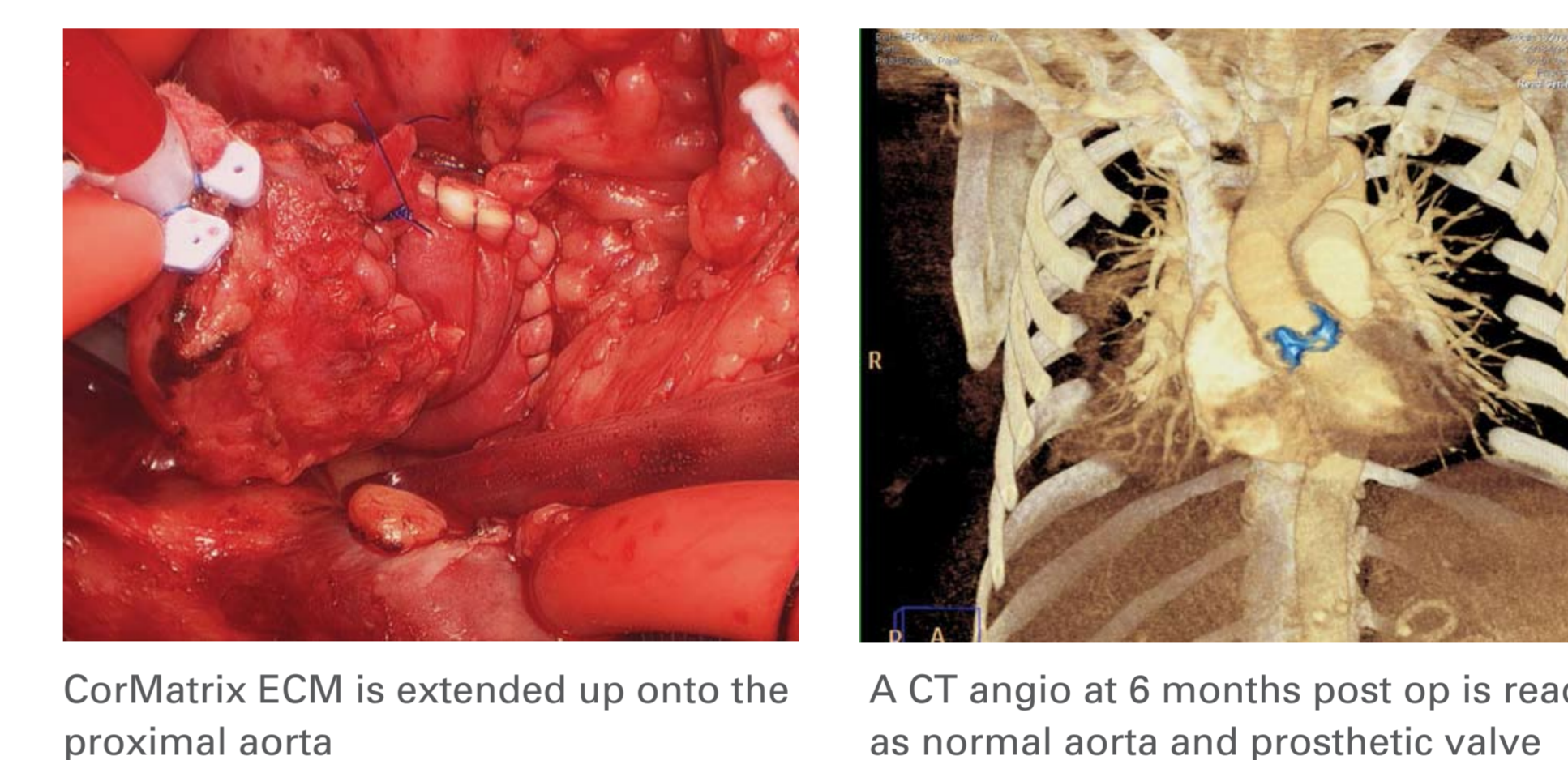
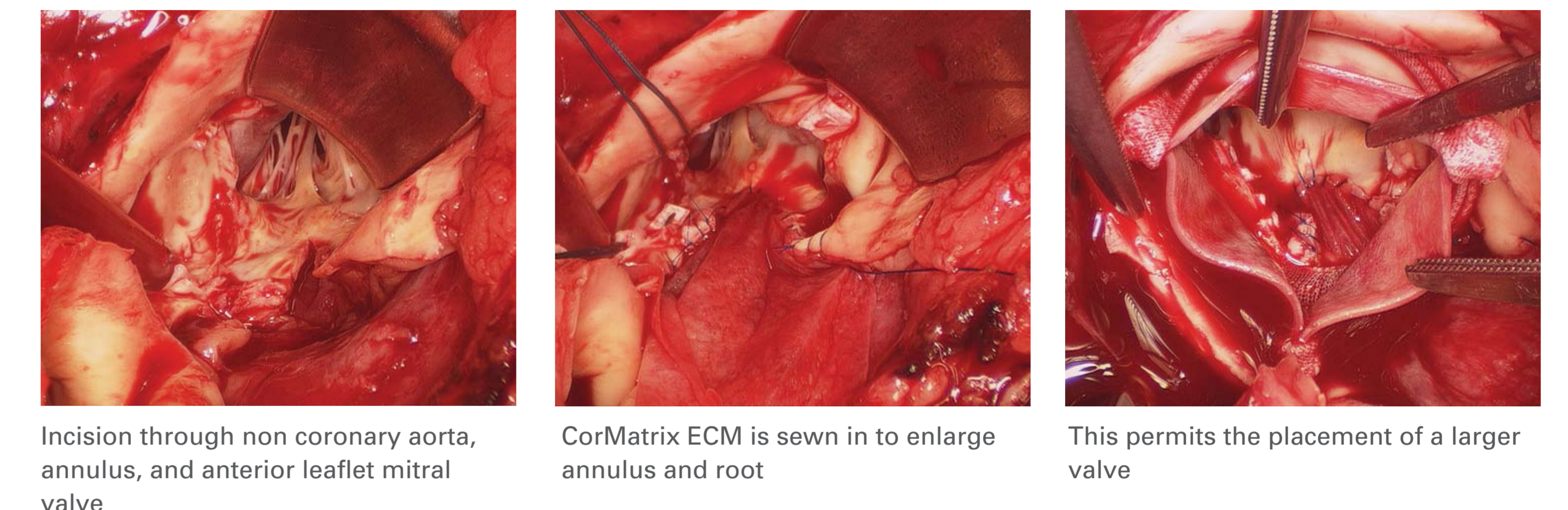
Valvular reconstruction using xenografts elicits foreign body response and calcification. Valve repair is preferred over replacement but can be limited by native tissue destruction. Small intestine submucosa extracellular matrix (ECM) is recently available for intra-cardiac repair. ECM acts as a scaffold for patients' cells to differentiate into site specific tissue constructs. This study determines feasibility and function of ECM valvular reconstruction.

Methods:

From February to November 2008, valvular reconstructions were performed using CorMatrix ECM. Procedures were 7 aortic root enlargements, 1 mitral posterior leaflet replacement, 3 mitral anterior leaflet reconstructions and 1 aortic leaflet repair. Other applications included unroofed coronary sinus, ASD and ascending aorta repair. ECM was tailored and sewn to native tissue, edge to edge with running 4-0 or 5-0 poly-propylene. For root enlargements, a patch traversed from within mitral anterior leaflet, across annulus, wrapping anteriorly, expanding the aorta. Valve reconstructions ranged from segmental to near complete leaflet replacement. Detailed intra-operative photography, follow-up echocardiography and CT-angiography, were used to evaluate architecture and function.

Results:

CT angiography of the first aortic root enlargement at 30 weeks, shows a normal aorta. By then, the ECM is replaced by patient tissue. Follow-up echocardiography from 1-9 months, for all other reconstructions, reveals excellent function.



Conclusions:

The availability of ECM for intra-cardiac reconstruction introduces the first opportunity to re-grow portions of valve architecture. The acellular ECM provides support and function, while the newly created tissue replaces the matrix. As a result, calcification of xenograft implants is avoided and valves are preserved, that might otherwise be replaced.